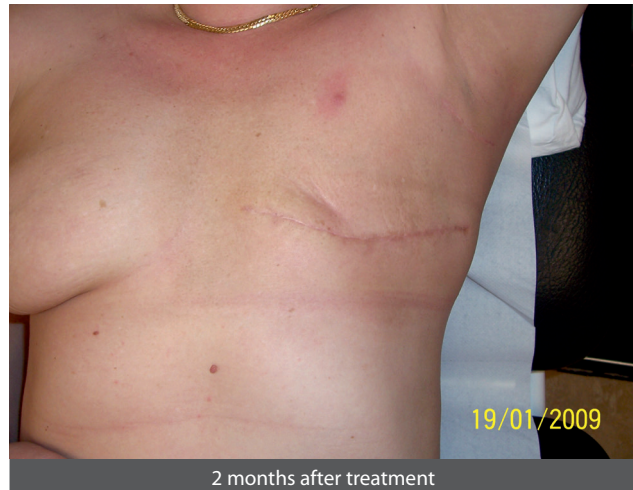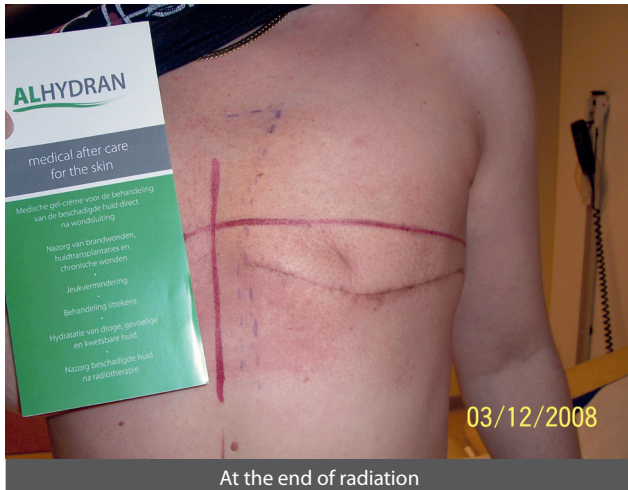


Case ALHYDRAN: Radiotherapy

1. Case study description

patient age	42 years
gender	female
diagnosis	breast carcinoma
therapy after care	ALHYDRAN during and after the radiation period

2. Evolution of the skin



3. Conclusions medical team

- ALHYDRAN is a good alternative for cetomacrogol
- Patients are almost always positive about its use
- ALHYDRAN is better than an Aloe Vera gel only, due to hydrating properties of ALHYDRAN. If only a gel is used, the radiated skin will become too dry and flaky
- ALHYDRAN is used with grade I and II radiation dermatitis

4. Patient experience

- ALHYDRAN is better than an indifferent cream (cetomacrogol), because ALHYDRAN eliminates the pain of radiation skin burn
- Reduces itching
- ALHYDRAN was easy to apply and has a neutral odour

Case study: N.S. Russell, radiotherapist, Netherlands Cancer Institute (NKI), Antoni van Leeuwenhoek Hospital, Amsterdam, The Netherlands