

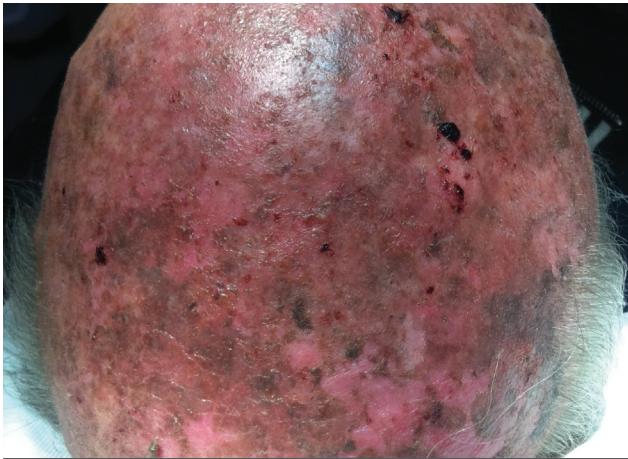
Case ALHYDRAN:

Multiple actinic keratosis

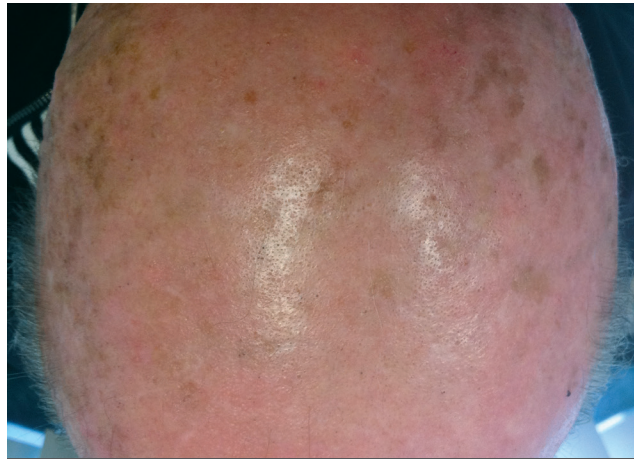1. Case study description

patient age	81 years
gender	male
diagnosis	actinic keratosis of the scalp
treatment	a single session of 5-ala PDT
therapy after care	ALHYDRAN twice daily

2. Evolution of the skin



Start of ALHYDRAN as a single treatment, applied twice a day



Day 7 after starting ALHYDRAN

3. Conclusions medical team

- Day 1 after PDT, patient was seen during an emergency consultation with serious reactions: inflamed erythema, erosions, crusting
- Good and quick clinical improvement (within a week)

4. Patient experience

- Complaints of pain disappeared within 48 hours
- ALHYDRAN had a cooling effect

Case study: Dr. R. Ceulen, Dermatologist, Albert Schweizer Hospital, Dordrecht, The Netherlands